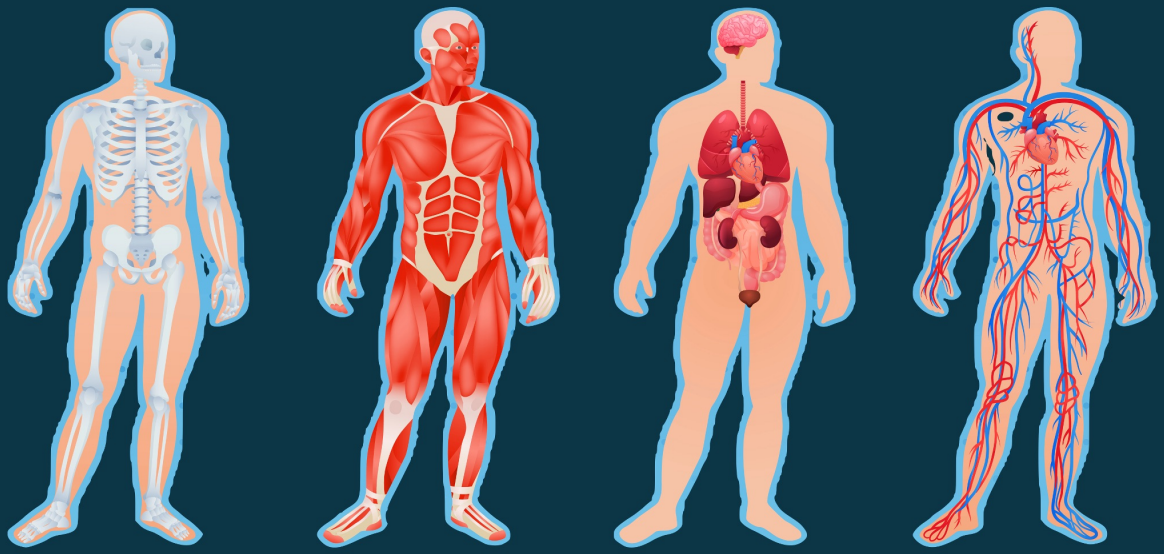
ANATOMY BODY SYSTEMS

CASE STUDY BUNDLE



11 Medical Case Studies

Differentiated versions

- Use the TEAMS version to make it an interactive class experience! Perfect for class support or just for fun!

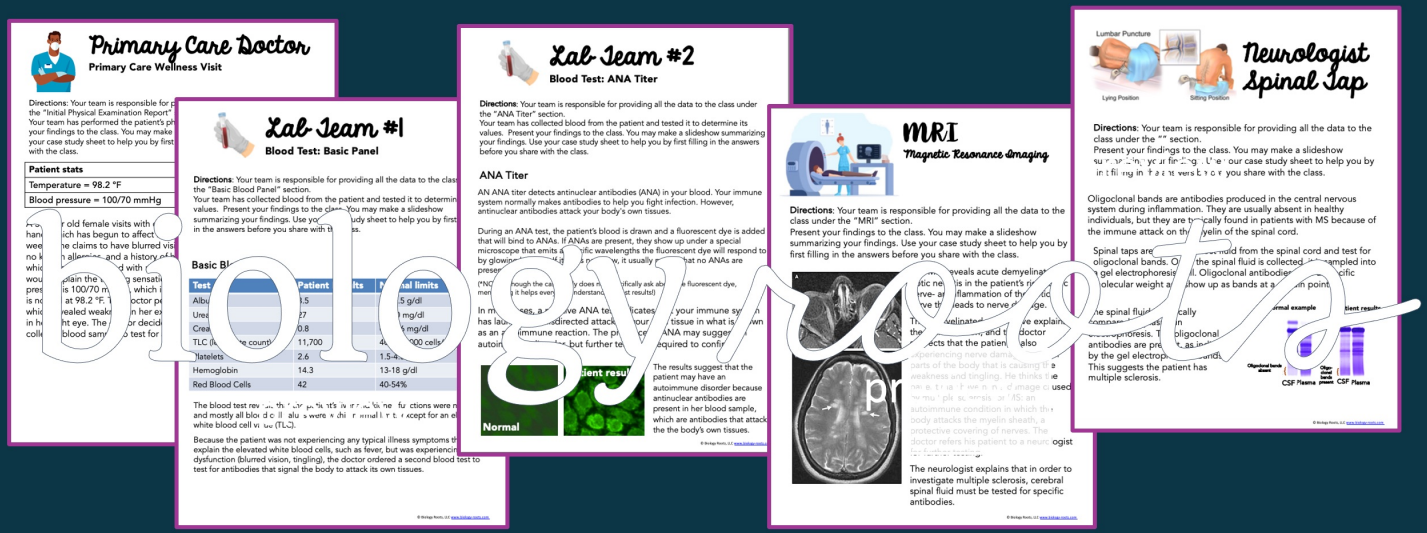


Doctor or Lab Team

Teacher Directions

Alternate version

To make this case study more engaging, you can have students form "teams" to complete this case study as a class. Each doctor or lab team present their findings. Please note that this may take longer than the other version of the case study, where all the information is available right on the paper, and students work in partners independently without class presentations.



Digital version of case studies included

Search Google or type a URL

Nervous System Case Study ©Biology Roots

USE TEMPLATE

CASE STUDY: Blurred Vision

A 39 year old female visits her doctor with complaints of tingling fingers on her left hand, which has begun to affect her arm and neck. For the past two weeks, she claims to have blurred vision in her right eye. The patient has no known allergies, and a history of hypertension (high blood pressure) which is being managed with medication, but otherwise nothing that would explain the tingling sensation or blurred vision. Her current blood pressure is 100/70 mmHg, which is within normal limits. Her temperature is normal at 98.2 °F. The doctor performed a basic physical examine which revealed weakness in her extremities and confirmed blurred vision in her right eye. The doctor decides to send the patient to the lab to collect a blood sample to test for any underlying abnormalities.

The blood test reveals that the patient's liver and kidney functions were normal, and mostly all blood cell values were within normal limits except for an elevated white blood cell value (TLC).


Test	Patient Results	Normal limits
Albumin	3.5	3.5-5.5 g/dl
Urea	27	20-40 mg/dl
Creatine	0.8	0.6-1.6 mg/dl
TLC (leukocyte count)	11,700	4000-11000 cells/mm
Platelets	2.6	1.5-4.5
Hemoglobin	14.3	13-18 g/dl
Red Blood Cells	42	40

Because the patient was not experiencing any typical illness symptom such as fever; but rather blurred vision and tingling, the doct ere an ANA titer: a test that detects antinuclear antibod your blood. Your immune system normally kes an o help you t infection. However, inuclear antibodies attack y body's own tissu

A tes ier bl d is aw nd presc d is ded t to A AN are esent ley ow o und a e mic cop rat emits wav th ll res by glowing brighter. If it does not glow, it usually ans th ANAs are present.

In most cases, a positive ANA test indicates that your immune system has launched a misdirected attack on your own tissue in what is known as an autoimmune reaction. The presence of ANA may suggest an autoimmune disorder, but further testing is required to confirm.





Your answer here

1

Google Slides

biology roots

MacBook Air

Hosted on Google Slides

Nervous System (Multiple Sclerosis)

CASE STUDY: BLURRED VISION

Name: _____ Date: _____

A 39 year old female visits her doctor with complaints of tingling which began to affect her arm and neck. For the past two weeks, she has had blurred vision in her right eye. The patient has no known allergies, and a history of hypothyroidism which is being managed with medication, but otherwise nothing significant. She denies any sensation or blurred vision. Her current blood pressure is 130/70 mmHg, and her pulse is 72 bpm. Her temperature is normal at 98.2 °F. The doctor performed a brief neurological exam and noticed weakness in her extremities and confirmed blurred vision in her right eye. She asked the patient to take the lab to collect a blood sample to test for any underlying conditions.

Test	Patient Results
Albumin	3.5
Urea	27
Creatine	0.8
TLC (leukocyte count)	11,700
Platelets	2.6
Hemoglobin	14.3
Red Blood Cells	42

The blood test reveals that the patient's liver and kidney function are normal. However, the blood cell values were within normal limits except for an elevated WBC count.

Because the patient was not experiencing any typical illness symptoms, the doctor suspected that the patient's symptoms were caused by an autoimmune disease. The doctor ordered an MRI and ANAs. If ANAs are present, they show up under a special microscope. The doctor explained that the patient's immune system was attacking healthy cells. The fluorescent dye will respond to by glowing brightly. This means that no ANAs are present.

In most cases, a positive ANA test indicates that your immune system is attacking your own tissue in what is known as an autoimmune disease. A positive ANA test does not always suggest an autoimmune disorder, but further testing is required to confirm a diagnosis.

Patient results

Normal

1. What is the problem?

2. What is multiple sclerosis? _____

3. What are oligoclonal bands and what do they indicate if they are found in fluid?

The doctor suggests the patient undergo a lumbar puncture to collect cerebral spinal fluid. The doctor explained that a lumbar puncture is a procedure where a needle is inserted between the vertebrae in the lower back to collect cerebral spinal fluid. The patient was informed that the cerebral spinal fluid must be sampled and tested for oligoclonal bands.

Oligoclonal bands are antibodies produced in the central nervous system during an immune response. They are usually absent in healthy individuals, but in multiple sclerosis, the immune system attacks the myelin sheath of the spinal cord and nerves. This inflammatory response leads to the presence of these antibodies in the spinal fluid.

Lumbar Puncture

Lying Position

Sitting Position

Spinal taps are used to collect fluid from the spinal cord and test for oligoclonal bands. Once the fluid is collected, it is sampled into three separate tubes. Each tube is labeled with the patient's name, weight and show up as bands at different locations.

Normal exam

Oligoclonal bands present

CSF Plasma

The spinal fluid is clinically compared to plasma in electrophoresis. The oligoclonal antibodies are present, as indicated by the gel electrophoresis bands.

The brain and nerves are similar to an electrical system. The nerves communicate with the brain via electrical signals. The brain sends signals to the nerves to perform certain functions. The signals travel through the neuron, which is made up of the cell body, dendrites, and axon. The signal travels down the axon until it reaches the axon terminal, where it releases neurotransmitters to communicate with the next important part of the neuron.

Cell body

Axon terminal

Dendrites

Axon

Myelin sheath

Unmyelinated

Myelinated

Node of Ranvier

Myelin sheath

Direction of nerve impulse

The action potential chain reaction can "jump" from node to node, thanks to myelin.

The inflammation caused by multiple sclerosis strips away the myelin from neurons in what is known as demyelination. In multiple sclerosis, this causes signals to slow down, get misrouted, or fail to reach their destination. This results in mixed or abnormal firing of sensory nerves, which the brain interprets as unusual sensations such as tingling or numbness. It can also lead to other complications such fatigue, vision problems, trouble with speech or swallowing, weakness and coordination issues.

Fortunately, there are treatment options for patients with MS which can help manage the disease and slow down its progression. Some of these treatments include:

5. Explain what depolarization is and why it occurs as a chain reaction: _____

6. Explain how myelin enables neurons to communicate and send signals more quickly: _____

7. What is the underlying cause of multiple sclerosis? _____

8. Why do patients with multiple sclerosis experience things like tingling, numbness, fatigue, difficulty with speech, etc? _____

dendrites

Nerve cell body

Nerve cell axon

Myelin sheath

Demyelinated axon

Axon terminal

Myelin sheath

Normal axon

Demyelinated axon

Myelin sheath

Myelin sheath covers and protects the axon which send messages between cells. The myelin sheath is made up of fatty cells that provide insulation on an electrical wire. Myelin sheaths are found in the brain and nervous system. Myelin helps the nervous system function properly by allowing it to effectively send signals.

Immune System (Chronic Granulomatous Disease)

CASE STUDY: The Very Sick Boy

Name: _____ Date: _____

A 12 year old boy in Brazil visited his doctor with fever and respiratory symptoms including a cough and mucus that were present for 3 days. His temperature was 100.8°F and he was within normal limits at 98 bpm. The doctor suspected bacterial pneumonia and prescribed a course of antibiotics and suggested fever reducers such as ibuprofen or acetaminophen to help manage the body's fever.

Two days after the visit, the boy's father called the doctor's office to complain that the boy's fever did not break despite taking ibuprofen and finishing the course of antibiotics. The doctor suggested that the boy may be suffering from refractory fever—a fever that does not respond to medication.

During the intake exam at the hospital, the boy's temperature was 104.9°F. When listening to his lungs with a stethoscope, the doctor noticed that the boy's pneumonia was complicated with **pleural effusion** - fluid build up in the lungs. The boy was immediately put on intravenous amoxicillin—clavulanate (a type of antibiotic) for 10 days.

cervical adenopathy

After 10 days, his fever persisted, and he presented with swollen lymph nodes in his head and neck (cervical adenomegaly); and an enlarged spleen and liver (hepatosplenomegaly).

The hospital decided to engage several tests for specific infections: a TORCH screen, which is a blood test that tests for toxoplasmosis, rubella, herpes simplex, and HIV; a tuberculin skin test for tuberculosis, and a sputum AFB in which sputum is tested for bacteria (sputum is the thick, dark mucus that the lungs produce during respiratory illness).

Each test came back negative, which lead to inconclusive answers. The lab team sent him in for an x-ray which confirmed had pleural effusion (fluid in his lungs), but there was no sign of necrosis (tissue death). The next step was a biopsy of the boy's lymph nodes in the neck (cervical adenomegaly) to see if there was any tissue death.

One of the doctors suggested that the boy may have a rare disease called chronic granulomatous disease (CGD), which is a genetic disorder that affects the body's ability to fight off infections. The doctor explained that CGD

Integumentary System (Lamellar Ichthyosis)

CASE STUDY: The Scaly Girl

A 9 year old girl visits a physician with complaints of sore eyes because her eyelids cannot fully close. The doctor immediately notes the scales and redness on the patient's skin. She described her skin as constantly itchy, which was exacerbated in the summer heat, particularly when perspiring (sweating).

When asked about the patient's birth, the parents said she was covered in a membrane and could not breastfeed, prompting a nanogastric feeding tube. Her hairs were also noted to fall out slowly. Her mother says that the membrane she was covered in at birth progressed into scales, and she has had them ever since.

There was no other notable medical history for the patient. None of her siblings experienced the same condition. To manage her skin condition, the patient had hydrocortisone ointment for rash relief with no significant improvement.

Vital signs were all normal. Dermatological examination showed dry, scaly skin that represents ichthyosis: a group of genetic skin disorders. Ichthys is a Greek root word meaning "fish" or "scale". The patient's skin also included erosions (loss of epidermis) and fissures (cracks). On the scalp, thick scales and alopecia (hair loss) were present. Contractures of the joints were present on both hands and feet (a condition where joints become stiff and lose normal range of motion due to the shortening and/or tightening of surrounding tissues).

1. Based on the girl's symptoms, what body system(s) do you think is affected and why?

The parents' description of the girl being born in a membrane is typical of a collodion baby: a baby born with a tight, shiny covering. The collodion baby is the first sign of some forms of ichthyosis. There are many variations of ichthyosis. Read about possible types that the patient may have, and determine which one you think the patient has based on the information.

Ichthyosis vulgaris: can vary from very mild cases of dry skin to severe areas of thickened skin and scaling. The condition runs in families, often along with eczema and respiratory problems.

Ichthyosis vulgaris typically presents in early childhood, but an individual's skin will usually appear normal at birth. Symptoms may improve with age, and often subside in the warmer summer months, but worsen in the winter.

Lamellar ichthyosis: typically born with a collodion membrane, a tight, clear covering that sheds after a few weeks. The skin then becomes very red and covered by dark, scaly, plates all over the body, especially on the fingers and toes. Ectropion, eclabium, and alopecia are common. Some babies are born with no skin covering, and some patients ... skin very ... some patients ... often pulled outward, known as ectropion, and ... glands under the eyelids to ... to compare the ... to ... to ... to

Snippets...

CASE STUDY: The Very Sick Boy

A 12 year old boy in Brazil visited his doctor with fever and respiratory symptoms including cough and mucus that were present for 3 days. His temperature was 100.8°F and his heart rate was within normal limits at 98 bpm. The doctor suspected bacterial pneumonia and prescribed a course of antibiotics; and suggested fever reducers such as ibuprofen or acetaminophen to manage the boy's fever.

Two days after the visit, the boy's father called the doctor's office to complain that the boy's fever did not break despite taking ibuprofen twice a day, and his symptoms had not cleared up with antibiotics. The doctor suggested that the boy go to the hospital as he was concerned with the boy's **refractory fever** – a fever that does not respond to fever-reducing medications.

Name: _____ Date: _____

CASE STUDY: The Scaly Girl

A 9 year old girl visits a physician with complaints of sore eyes because her eyelids cannot fully close. The doctor immediately notes the scales and redness on the patient's skin. She described her skin as constantly itchy, which was exacerbated in the summer heat, particularly when perspiring (sweating).



When asked about the patient's birth, the parents said she was covered in a membrane and could not breastfeed, prompting a nasogastric feeding tube. Her hairs were also noted to fall out slowly. Her mother says that the membrane she was covered in at birth progressed into scales, and she has had them ever since.

Snippets...

Name: _____ Date: _____

CASE STUDY: A Bad Tummy Ache

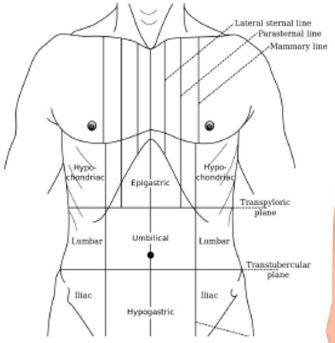
A 60-year-old man is admitted with complaints of severe, constant upper abdominal pain, nausea, and vomiting. He mentioned rapid weight loss in the past month and appears thin, and is wincing and clutching his abdomen. His temperature is slightly elevated at 100.4°F; his blood pressure is normal at 100/60 mm Hg; with normal pulse of 90 beats per minute. His abdomen is slightly distended and bowel sounds are hypoactive (reduced; indicating lower digestive activity). There is marked direct tenderness in response to light tapping in the midepigastrium.

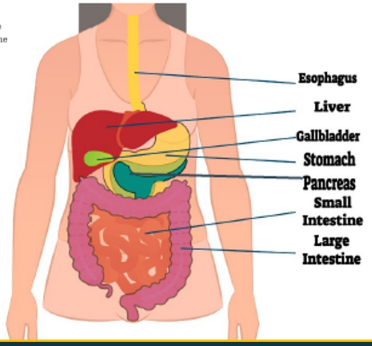
1. Circle or highlight the line on the diagram at right that depicts where the midepigastrium area is.

2. What internal organs are within or near the epigastrium area?

_____

_____





Please see the individual previews for more!